

DISEASES & CONDITIONS

# Osteoporosis and Spinal Fractures

As we get older, our bones get thinner and our bone strength decreases. Osteoporosis is a disease in which bones become very weak and more likely to break. It often develops unnoticed over many years, with no symptoms or discomfort until a bone breaks.

Fractures caused by osteoporosis most often occur in the spine. Spinal fractures – called vertebral compression fractures – occur an estimated 1.5 million times each year in the United States. They are almost twice as common as other fractures typically linked to osteoporosis, such as broken hips and wrists.

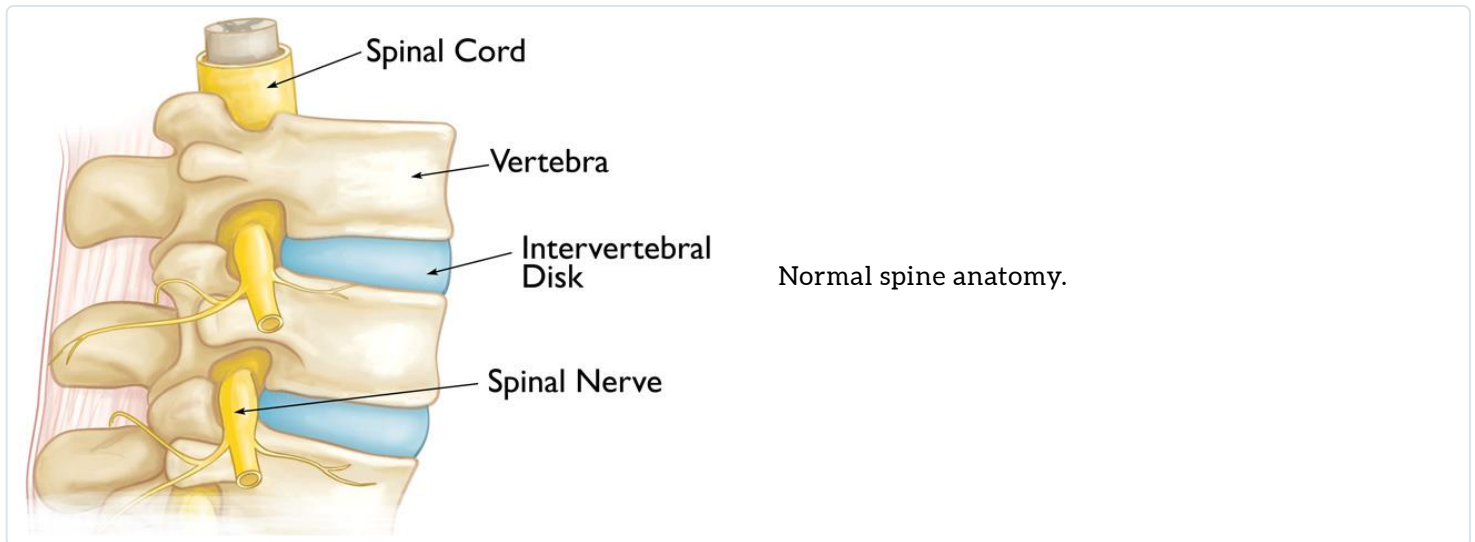
Not all vertebral compression fractures are due to osteoporosis. But when the disease is involved, a fracture is often a patient's first sign of a weakened skeleton from osteoporosis. To learn more about osteoporosis: [Osteoporosis\(/en/diseases--conditions/osteoporosis/\)](https://orthoinfo.aaos.org/en/diseases--conditions/osteoporosis/).

## Anatomy

Your spine is made up of 24 bones, called vertebrae, that are stacked on top of one another. These bones connect to create a canal that protects the spinal cord. Other parts of your spine include:

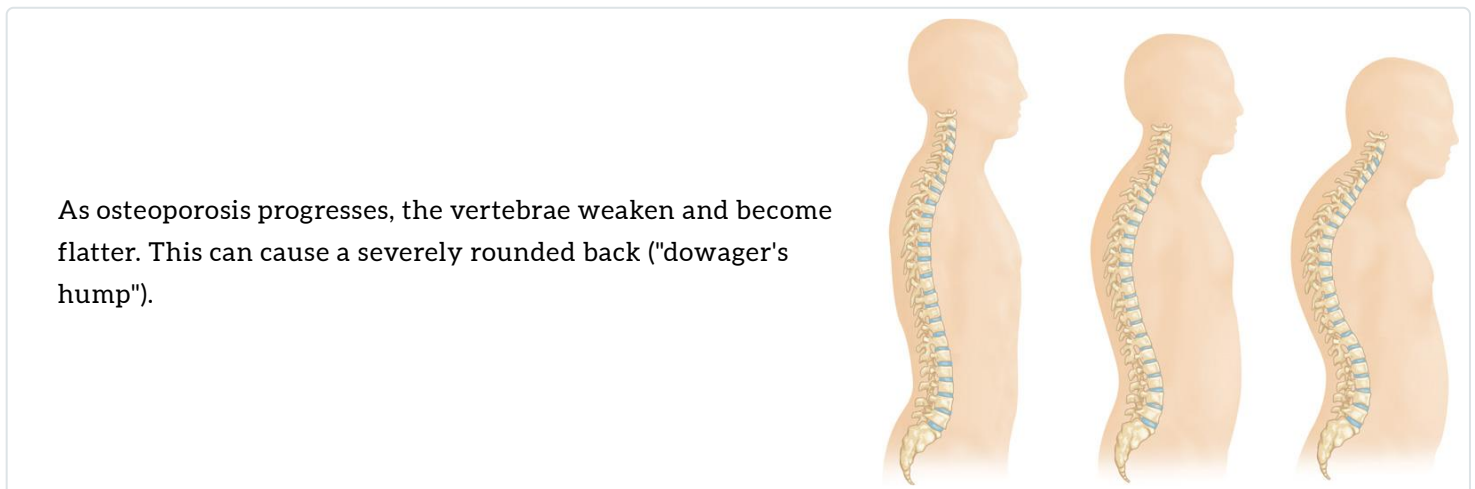
**Spinal cord and nerves.** These "electrical cables" travel through the spinal canal carrying messages between your brain and muscles. Nerve roots branch out from the spinal cord through openings in the vertebrae.

**Intervertebral disks.** In between your vertebrae are flexible intervertebral disks. These flat, round disks are about a half-inch thick. They cushion the vertebrae, acting as shock absorbers when you walk or run.

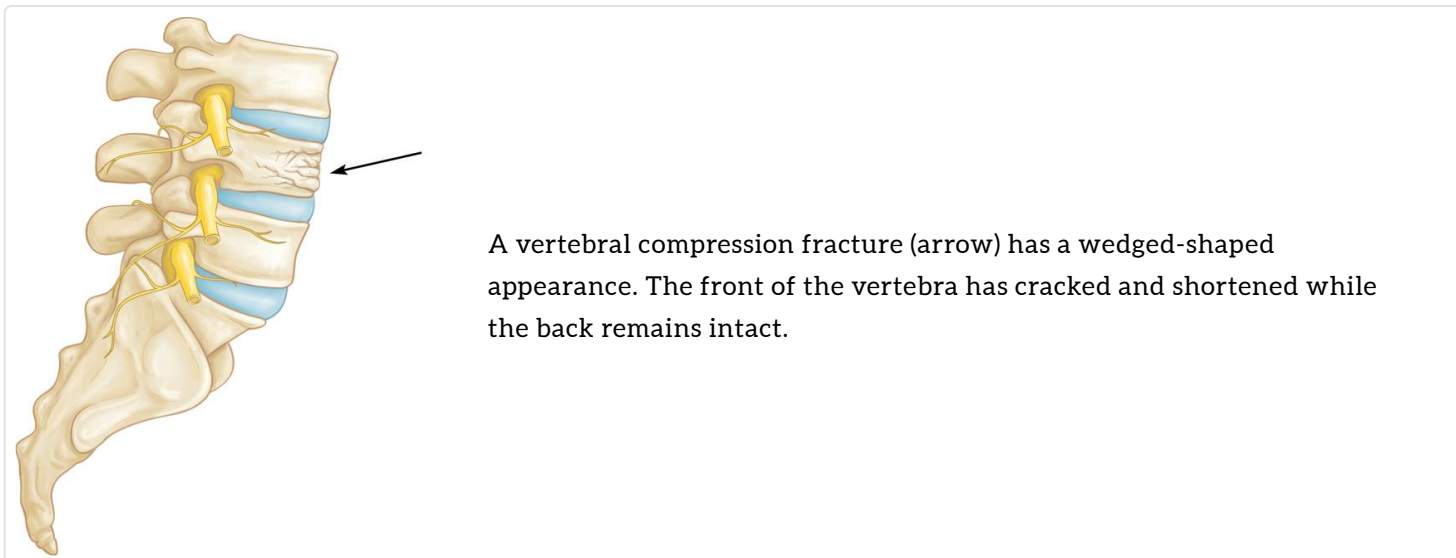


## Cause

Osteoporosis is a natural phenomenon that occurs with aging. As we get older, our bones weaken. When the vertebrae in the spine weaken, they can narrow and become flatter. This can make elderly patients shorter and lead to a rounded back, a hump, or a bent-forward look to the spine.



The weakened vertebrae are at a high risk for fracture. A vertebral compression fracture occurs when too much pressure is placed on a weakened vertebra, and the front of it cracks and loses height. Vertebral compression fractures are often the result of a fall, but people with osteoporosis can suffer a fracture even when doing everyday things, such as reaching, twisting, coughing, and sneezing.



## Symptoms

A vertebral compression fracture causes back pain. The pain typically occurs near the break itself. Vertebral compression fractures most commonly occur near the waistline, as well as slightly above it (mid-chest) or below it ([lower back\(/en/diseases--conditions/low-back-pain/\)](https://orthoinfo.aaos.org/en/diseases--conditions/low-back-pain/)).

The pain often gets worse with motion, particularly when you are changing positions. It is often relieved by rest or lying down. Coughing and sneezing can also make the pain increase. Although the pain may move to other areas of the body (for example, into the abdomen or down the legs), this is uncommon. If the fracture is severe enough, it can cause nerve pain that radiates into the legs.

## Doctor Examination

### *Physical Examination*

Your doctor will talk with you about your general health and medical history and ask you to describe your symptoms. They will then perform a physical exam.

While you are standing, your doctor will examine the alignment, or straightness, of your spine and your posture. They will also push on certain places on your back to try and identify whether your pain is from an injury to the muscle or bones.

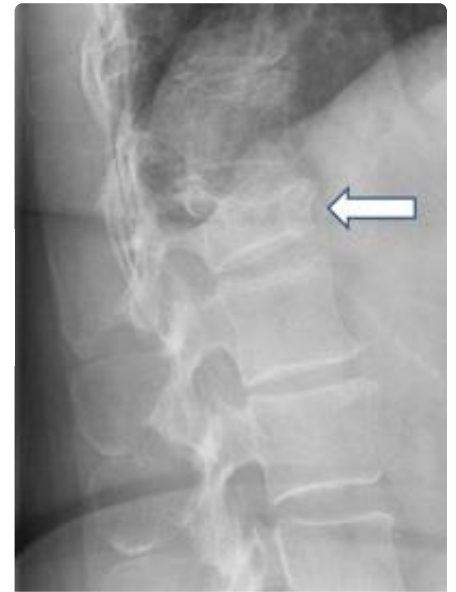To make sure there is no injury to the spinal nerve roots, your doctor will conduct a neurologic examination – looking for loss of sensation, changes in reflexes, or muscle weakness.

### *Imaging Tests*

Imaging tests will provide important information about your fracture and will help your doctor determine whether your injury is new (acute) or older (chronic).

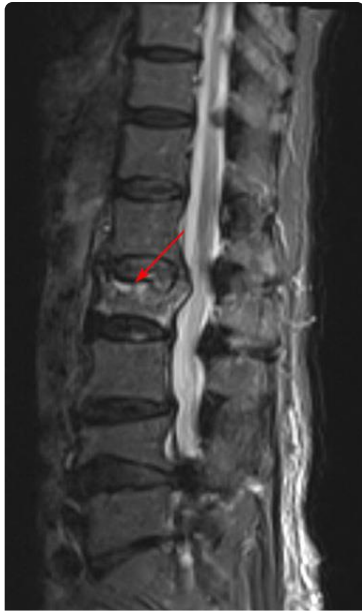**X-rays.** X-rays provide images of dense structures, such as bones. If your doctor suspects a vertebral compression fracture, they will order an X-ray to confirm the diagnosis.

This X-ray shows the side view of vertebra that has narrowed, losing its typical rectangular shape.



Other problems in the spine may also show up on X-rays. Elderly patients with a vertebral compression fracture may also have narrowing of disk spaces (degenerative disk disease) and/or [scoliosis \(/en/diseases--conditions/introduction-to-scoliosis/\)](#), which is a sideways curve of the spine.

**Magnetic resonance imaging (MRI) scan.** An MRI will show any damage to the soft tissues around the fracture (nerves and disks) in better detail. Because of how it shows bone, an MRI may help your doctor determine the age of the fracture. Where there is a new fracture, the involved bone will appear brighter than the surrounding bone. This suggests edema, or inflammation, in the area. If the fracture is old, the bone will appear normal.



In this MRI, the bright appearance of the fractured vertebra indicates edema, or inflammation, an indication of a new fracture.

**Bone scan.** A bone scan can pick up any abnormal activity in bone, including the presence of fractures. It can also sometimes show whether a fracture is acute or chronic.

**Computed tomography (CT) scan.** A CT scan shows both soft tissue and bone. It can help your doctor evaluate whether your fracture has extended into your spinal canal, where your spinal cord and nerve roots are located.

## ***Bone Density Testing***

When you have a vertebral compression fracture, it is important to assess whether you also have osteoporosis and, if so, how severe the condition is. X-rays will often show thinning of the bone throughout the spine – a condition known as osteopenia, or low bone mass. Osteopenia is a forerunner to osteoporosis, in which the bone becomes much more fragile and prone to fractures.

The extent of bone loss can be determined with Dual-Energy X-ray Absorptiometry (DEXA), a type of bone mineral density scan. The results of the DEXA will help your doctor estimate your risk for additional fractures in the spine and in other parts of your body. The DEXA results will help your doctor determine whether to treat your bone density loss with medications.

Osteoporosis treatment is crucial, as it has been found that more than 30% of people with a compression fracture in their spine are likely to sustain another fracture within a year.

## **Treatment**

### ***Nonsurgical Treatment***

Fortunately, most people who suffer a vertebral compression fracture get better within 3 months without specific treatment to repair the fracture. Simple measures, such as a short period of rest and limited use of pain medications, are often all that is required. In some cases, patients are instructed to wear a brace to restrict movement and allow the vertebral compression fracture to heal.

It is important to note that when the fracture heals, the bone does not reform into its original rectangular shape, but if it is healed, it will not cause further collapse.

If your doctor has also diagnosed osteoporosis, you are at increased risk for additional vertebral compression fractures and other fractures, such as to the hip and wrist. Your doctor will address treatments for bone density loss during this time.

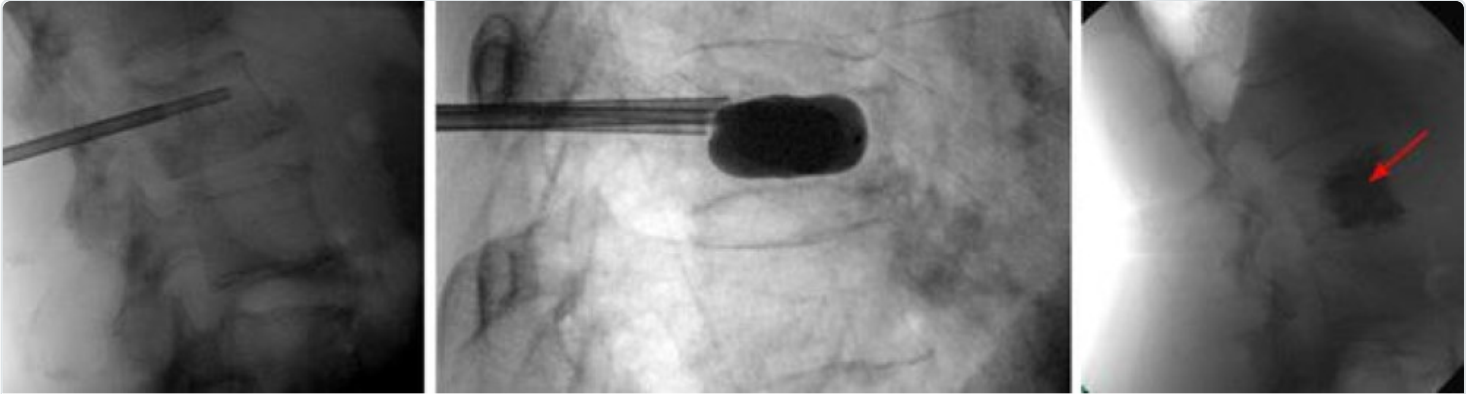
## ***Surgical Treatment***

If you have severe pain that does not respond to nonsurgical treatment, surgery may be considered.

In the past, the only surgical options available to patients with vertebral compression fractures involved extensive procedures. Today, vertebral augmentation procedures offer a minimally invasive alternative.

The two types of vertebral augmentation methods available are kyphoplasty and vertebroplasty. The best candidates for these procedures are patients who suffer severe pain from recent vertebral compression fractures. If you are a candidate for kyphoplasty or vertebroplasty, your doctor will talk with you about which procedure may be better for you based on the type of vertebral compression fracture you have.

**Kyphoplasty.** In a kyphoplasty, the surgeon inserts a needle into the fractured vertebra using an X-ray for guidance. The surgeon then inserts a small device called a balloon tamp through the needle and into the fractured vertebra. The balloon tamp is inflated from within the vertebra, which restores the height and shape of the vertebral body. When the balloon tamp is removed, it leaves a cavity that is filled with a special bone cement that strengthens the vertebra.

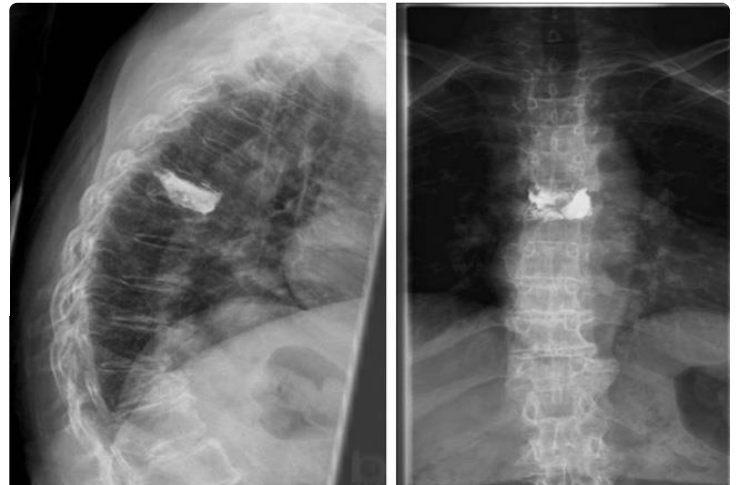


In kyphoplasty surgery: **(Left)** The surgeon places a needle into the fractured vertebra. **(Center)** A balloon tamp is then inserted and inflated inside the bone. **(Right)** The empty cavity is filled with bone cement (arrow) to strengthen the vertebra.

Kyphoplasty can be performed using general anesthesia (which puts you to sleep) or with a local anesthesia (which numbs your body around the fracture site). For this procedure, the patient lies face down on the operating table, and the surgeon accesses the spine from the back.

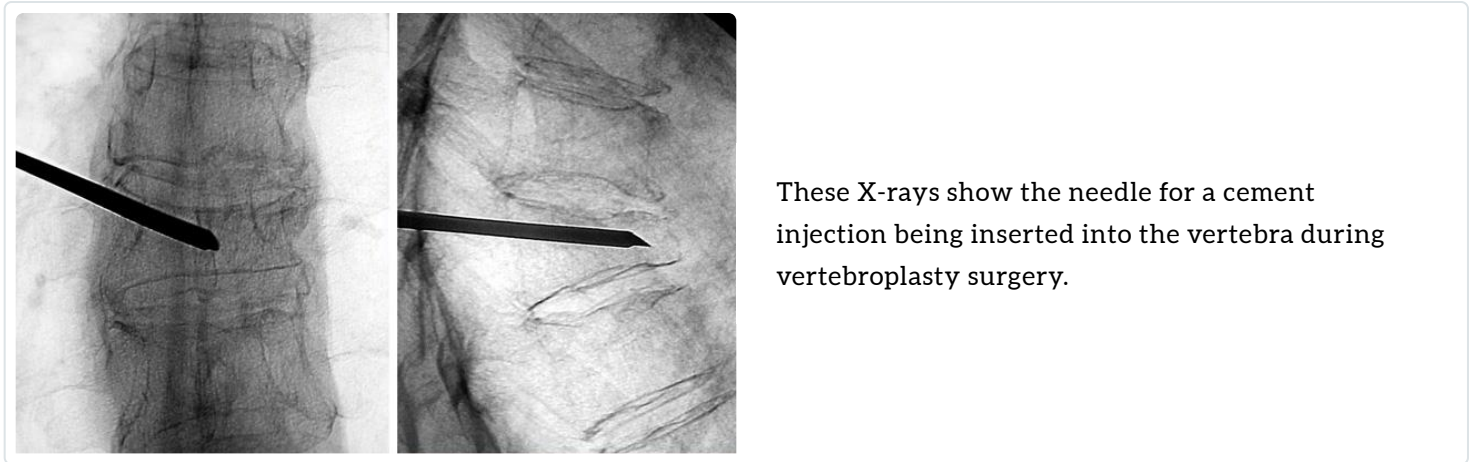
After surgery, patients can go back to all their normal activities of daily living as soon as possible with no restrictions.

These X-rays show **(left)** a side-view and **(right)** a front-view of the spine after kyphoplasty surgery.



**Vertebroplasty.** Vertebroplasty is a technique similar to kyphoplasty, but the surgeon does not use a balloon tamp to create a space for the cement. Instead, the surgeon injects the cement directly into the narrowed vertebra. Like kyphoplasty, this procedure is performed while the patient is lying face down so that the surgeon can access the fractured vertebra from the back.

After this surgery, patients are encouraged to return to their normal, day-to-day activities as soon as possible.



Discuss with your surgeon which procedure may be better for you.

## ***Surgical Outcomes***

Several reports have been published on the results of vertebral augmentation procedures. In two large studies, the benefit of vertebroplasty was found to be very short term. In contrast, studies indicate that kyphoplasty may increase function and decrease pain more quickly than nonoperative treatment.

Your doctor will discuss realistic expectations for recovery if vertebroplasty or kyphoplasty is recommended for you.

### **Last Reviewed**

November 2021

### **Contributed and/or Updated by**

[Daniel K. Park, MD, FAAOS](#)

[Louis G. Jenis, MD](#)

### **Peer-Reviewed by**

[Thomas Ward Throckmorton, MD, FAAOS](#)

[Stuart J. Fischer, MD](#)

[Colin F. Moseley, MD](#)

[Daniel K. Park, MD](#)

AAOS does not endorse any treatments, procedures, products, or physicians referenced herein. This information is provided as an educational service and is not intended to serve as medical advice. Anyone seeking specific orthopaedic advice or assistance should consult his or her orthopaedic surgeon, or locate one in your area through the AAOS [Find an Orthopaedist](#) program on this website.